

UWL REPOSITORY
repository.uwl.ac.uk

Investigation of robust visual reaction and functional connectivity in the rat brain induced by rocuronium bromide with functional MRI

Zhou, Wenchang, Cai, Aoling, Nie, Binbin, Wen, Zhang, Yang, Ting, Zheng, Ning, Manyande, Anne ORCID logoORCID: <https://orcid.org/0000-0002-8257-0722>, Wang, Xuxia, Xu, Fuqiang, Tian, Xuebi and Wang, Jie (2020) Investigation of robust visual reaction and functional connectivity in the rat brain induced by rocuronium bromide with functional MRI. *American Journal of Translational Research*, 12 (6). pp. 2396-2408. ISSN 1943-8141

PMC7344061

This is the Published Version of the final output.

UWL repository link: <https://repository.uwl.ac.uk/id/eprint/7211/>

Alternative formats: If you require this document in an alternative format, please contact: open.research@uwl.ac.uk

Copyright: Creative Commons: Attribution-Noncommercial 4.0

Copyright and moral rights for the publications made accessible in the public portal are retained by the authors and/or other copyright owners and it is a condition of accessing publications that users recognise and abide by the legal requirements associated with these rights.

Take down policy: If you believe that this document breaches copyright, please contact us at open.research@uwl.ac.uk providing details, and we will remove access to the work immediately and investigate your claim.

Rights Retention Statement:

Original Article

Investigation of robust visual reaction and functional connectivity in the rat brain induced by rocuronium bromide with functional MRI

Wenchang Zhou^{1*}, Aoling Cai^{2,3*}, Binbin Nie^{4,5*}, Wen Zhang¹, Ting Yang¹, Ning Zheng^{3,5}, Anne Manyande⁶, Xuxia Wang^{3,5}, Fuqiang Xu^{2,3,5,7}, Xuebi Tian¹, Jie Wang^{3,5,8}

¹Department of Anesthesiology, Tongji Hospital, Tongji Medical College, Huazhong University of Science and Technology, Wuhan 430070, Hubei, P. R. China; ²Wuhan National Laboratory for Optoelectronics, Huazhong University of Science and Technology, Wuhan 430074, Hubei, P. R. China; ³Center of Brain Science, State Key Laboratory of Magnetic Resonance and Atomic and Molecular Physics, National Center for Magnetic Resonance in Wuhan, Key Laboratory of Magnetic Resonance in Biological Systems, Wuhan Institute of Physics and Mathematics, Innovation Academy for Precision Measurement Science and Technology, Chinese Academy of Sciences, Wuhan 430071, Hubei, P. R. China; ⁴Key Laboratory of Nuclear Radiation and Nuclear Energy Technology, Institute of High Energy Physics, Chinese Academy of Sciences, Beijing 100049, P. R. China; ⁵University of Chinese Academy of Sciences, Beijing 100049, P. R. China; ⁶School of Human and Social Sciences, University of West London, London, UK.; ⁷Center for Excellence in Brain Science and Intelligence Technology, Chinese Academy of Sciences, Shanghai 200031, P. R. China; ⁸Hebei Provincial Key Laboratory of Basic Medicine for Diabetes, 2nd Hospital of Shijiazhuang, Shijiazhuang 050051, Hebei, P. R. China. *Equal contributors.

Received November 22, 2019; Accepted May 21, 2020; Epub June 15, 2020; Published June 30, 2020

Abstract: Functional magnetic resonance imaging (fMRI) has been used extensively to understand the brain function of a wide range of neurological and psychiatric disorders. When applied to animal studies, anesthesia is always used to reduce the movement of the animal and also reduce the impacts on the results of fMRI. Several awake models have been proposed by applying physical animal movement restrictions. However, restraining devices were designed for individual subject which limits the promotion of fMRI in awake animals. Here, a clinical muscle relaxant rocuronium bromide (RB) was introduced to restrain the animal in fMRI scanning time. The fMRI reactions of the animal induced with RB and the other two commonly used anesthesia protocols were investigated. The results of the fMRI showed that there were increased functional connectivity and well-round visual responses in the RB induced state. Furthermore, significant BOLD signal changes were found in the cortex and thalamus regions when the animal revived from isoflurane, which should be essential to further understand the effects of anesthesia on the brain.

Keywords: Rocuronium bromide, isoflurane, animal anesthesia, fMRI, visual stimulation, resting state

Introduction

Due to its noninvasive imaging capacity and high spatial resolution [1], functional magnetic resonance imaging (fMRI) has been extensively used to understand the brain function of a wide range of neurological and psychiatric disorders [2, 3]. Combined with other research techniques, such as optogenetics, pharmacogenetics, and electrophysiology, fMRI technology provides great promise for exploring normal brain function, brain disease, or addiction. Thus, the preclinical fMRI study is a rapidly

growing field aimed at bridging the translational gap between animal and human research.

The state of consciousness is a very important parameter for investigation, especially in animal studies. To prevent stress and motion artifacts, the animals under investigation are always given general anesthesia, such as isoflurane [4], urethane [5], and propofol [6], etc. However, anesthetic agents could largely affect vascular reactivity and neurovascular coupling, which may result in changes of hemodynamic characteristics [7, 8], and alter brain metabo-

Cerebral activities induced by rocuronium bromide

lism, neural activity, neurovascular coupling, that seriously influence the results of fMRI [9].

In order to avoid the effects of anesthesia in fMRI studies, and bridge the gap between human and animal fMRI studies, several approaches have been proposed in recent years. There have been many prominent studies in the neuroscience community that utilized awake animal models in neurophysiological experiments in order to obtain better results [10-14]. The most commonly used awake animal model is the restraining model. Although restraining devices vary from laboratory to laboratory, the protocols are similar. Firstly, subjects are trained to accommodate to the noisy and immovable environment for MRI scanning. A restraining device is then placed on the subjects in formal scanning period [15-19]. However, most of the restraining devices are designed for individual subjects, and the subjects will become unstable when the scanning time is too long. Besides, head motion may also occur when stimulus is performed in the task-state fMRI with the restraining devices, especially nociceptive stimulus such as mechanical and heat pain. Furthermore, the restraint training for awake animal models could potentially cause long-lasting changes in the brain functional connectivity to pain and stress responses [20].

Rocuronium bromide (RB) is a commonly used muscle relaxant in modern anesthesia to facilitate rapid tracheal intubation or rapid sequence induction [21, 22]. As a N_2 acetylcholine receptor competitive binder, RB is able to selectively block the activity of skeletal muscles, minimizing the movement of subjects. Besides, it does not influence the function of the heart and blood vessels, which are important to the BOLD (Blood oxygenation level dependent) signal change in fMRI. The central nervous system is also insusceptible because rocuronium bromide cannot pass through the blood brain barrier. The use of a muscle relaxant has been reported to induce a robust result in pharmacological fMRI when 0.8% isoflurane and a neuromuscular blocker are administered [23]. These characteristics of rocuronium bromide make it an ideal agent to induce an immovable state in the fMRI study, which has less impact on the animal physiology and BOLD signal responses.

Currently, an approach that uses RB to restrain the animal in an fMRI study was proposed. An isoflurane induced group and a dexmedetomidine induced group were selected for comparison. The physiological parameters and the fMRI reaction in the task-state fMRI and resting-state fMRI were investigated. This study provides a new perspective in investigating the function of RB and may be essential for optimizing the anesthesia protocol of animal fMRI studies.

Material and methods

Animal preparation

Adult male Sprague-Dawley rats (200-400 g) were purchased from Hubei provincial center for disease control and prevention (P. R. China). All animals were housed under a 12 h light/dark cycle in constant temperature environment ($21 \pm 2^\circ\text{C}$) with food and water available *ad libitum*. All experiments were performed after at least three days' adaptation to the new environment. All animal experimental protocols were approved by the animal care and use committee of Wuhan Institute of Physics and Mathematics (2017-10068). Experimental procedures were conducted in accordance with the institutional guidelines and in compliance with Chinese laws and policies.

Physiological parameters detection

RB (bolus 10 mg/kg, maintained with 1.2 mg/kg/h) was used to restrain the animal according to a preliminary experiment and a bench study was performed to monitor the physiological parameters when subjects were restrained (**Figure 1**). Anesthesia was induced with 5.0% isoflurane, followed by oral endotracheal intubation, tail vein catheterization, and femoral artery catheterization. Lidocaine cream was used to reduce the excessive stimulation during endotracheal intubation and femoral artery catheterization. A small animal ventilator (Zhenhua, China) was used to maintain normal breathing of the animal (pump rate 80 bpm, tidal volume 10 mL/kg) when RB was injected into the subject. When the state of the animal became stable, physiological parameters were monitored at different isoflurane levels (1.5%-0%). Throughout the experiment, the mean arterial blood

Cerebral activities induced by rocuronium bromide

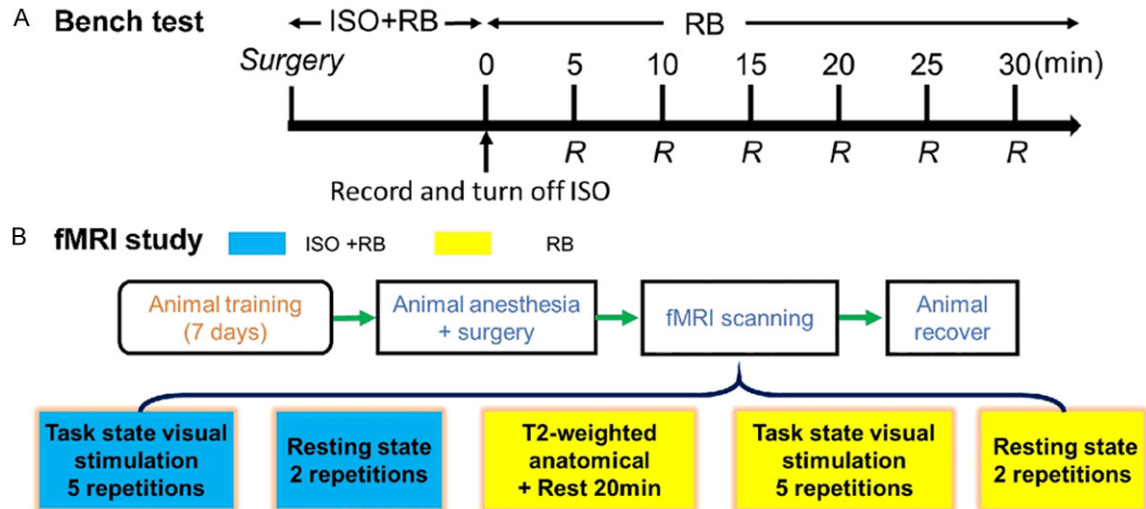


Figure 1. Flow charts of the experimental design. A. Bench study, the physiological parameters of subjects were monitored in ISO+RB state and RB state. The parameters in ISO+RB state were obtained when the animal was stable, and the RB state was obtained when isoflurane was removed. B. fMRI study, the same fMRI scanning protocol was performed in ISO+RB state and then RB state. Note: ISO: isoflurane; RB: Rocuronium bromide; fMRI: functional Magnetic Resonance Imaging; Task state: fMRI study with laser stimulation; Resting state: Resting state fMRI study.

pressure (MABP) and heart rate (HR) were continuously monitored using an electrocardiogram and blood pressure monitor, and the blood gas analysis was regularly measured through an automatic blood gas analyzer. Blood was withdrawn from the femoral artery and the same volume of saline was injected back into the animal to balance the blood pressure.

Preparation of MRI scanning

In order to reduce animal stress during MRI scanning, all subjects were trained outside the MRI scanner room before the official experiment. Training lasted seven days, and for 3-4 hours a day.

Before MRI scanning, the same operation as in the bench study was performed on subjects except for femoral artery catheterization. The anaesthetized animal was transferred to an MRI scanning bed and fixed with two ear sticks and a tooth stick. In order to perform controllable stimulation in the task-state fMRI, an optical fiber was fixed on the animal bed towards the right eye of the subject, connected with a laser generator (Anilab, China) and a programmable stimulator (Master-8, Israel). The left eye was covered to avoid interference. A small quilt and a warm water-cycling system

was used to maintain the body temperature of the subject. A pair of earplugs was used to reduce the noise of MRI scanning. The body temperature and respiration rate were monitored in real-time.

MRI acquisition

MRI experiments were conducted using a Bruker Biospec70/20USR small animal MR system (Bruker, Germany) operating at 300 MHz (7T). A 10 mm surface coil was used for signal reception and a partial volume transmit coil (Bruker, Germany). Functional BOLD images were obtained using single-shot spin-echo planar imaging sequence (SE-EPI) with the following parameters: FOV = 28×28 mm³, matrix size = 70×70, TR = 1500 ms, TE = 14 ms, segments = 2, number of average = 1, spatial resolution = 0.4×0.4 mm², slice thickness = 0.8 mm, 18 slices without gap. For the resting-state fMRI, 300 volumes were acquired when animal physiological parameters remained stable while for the task-state fMRI, 58 volumes were acquired when the programmed laser was given. The programmed laser was generated by the laser generator and a programmable stimulator Master-8 (487 nm, 200 μW, 20 Hz, 10 ms pulses, 24 s training after 60 s baseline measurement). A T2-weighted high resolution was obtained using

Cerebral activities induced by rocuronium bromide

fast spin-echo sequence (Turbo-RARE) with the same geometry as the functional image (spatial resolution = $0.11 \times 0.11 \text{ mm}^2$).

Induction of anesthesia

The MRI study was performed under three different anesthetic protocols (**Figure 1**). In the ISO-group, animals were anesthetized with RB (bolus 10 mg/kg, maintained with 1.2 mg/kg/h) and isoflurane (1.0-1.5%). For the RB-group, animals were induced with RB only (bolus 10 mg/kg, maintained with 1.2 mg/kg/h). In the MED-group, the animal was induced with dexmedetomidine only (maintained with 0.1 mg/kg/h).

MRI data preprocessing

All fMRI data was preprocessed with spm12 (<http://www.fil.ion.ucl.ac.uk/spm/>), DPABI (<http://rfmri.org/dpabi>) and spmratIHEP [24]. The MRI data was first converted to NIFTI format using the Bru2Anz converter (<https://people.cas.sc.edu/rorden/micro/Bru2anz>). Slice timing and head motion correction were performed on all functional images using spm12. The parameters estimated by the head motion correction were transformed to the FD Jenkinson value using DPABI which were used to estimate the movement of subjects. The functional images were normalized to a home-made rat brain template and spatially smoothed with a Gaussian kernel FWHM of $0.8 \times 0.8 \times 1.6 \text{ mm}^3$. Finally, the external brain tissue was removed from all of the normalized images.

Statistical analysis

Statistical analysis on animal physiological parameters under different anesthetic protocols (ISO-group and RB-group) were performed using two-sample student's test, and significant differences were shown when $P < 0.05$. The comparison of the mean FD Jenkinson among the three groups (ISO-group, RB-group and MED-group) were performed using one-way analysis of variance (ANOVA), and significant differences were shown when $P < 0.05$.

For task-state fMRI analysis, the preprocessed fMRI data were analyzed on a voxel-by-voxel basis using generalized linear model (GLM) based on the laser stimulation pattern, and the head motion parameters were imported as

regressors. All the evoked voxels were obtained and the statistical results were calculated using the permutation test. Significant regions were shown utilizing the voxel threshold-free cluster enhancement (TFCE) $P < 0.05$ and the cluster size > 8 voxels. The time course of each subject was further extracted based on the evoked regions. All of the time courses were normalized by their baseline, and the mean and variance of each groups were shown.

For resting-state fMRI, the preprocessed fMRI data were detrended, covariant regressed and filtered (0.01-0.1 Hz) using DPABI. A series of regions of interest (ROIs) were defined according to the rat brain anatomic atlas [25], which are listed in [Table S1](#). Functional connectivity (FC) of ROI-ROI or ROI-voxels were computed using Pearson correlation, and Fisher z-transformation was performed before statistical analysis. At ROI-voxels analysis, left DLG was set as the ROI, and FC intensity was computed from voxel to voxel. One-sample *t*-test was used for statistical analysis, and significant correlated regions with left DLG were shown based on the *t*-state. For ROI-ROI analysis, one-way ANOVA was used for statistical analysis among the three groups, and post hoc test Dunnett-*t* test ($P < 0.05$) was used to show statistical differences between the RB-group and the other two groups.

In order to evaluate the BOLD signal changes from ISO-state to RB-state, the resting-state fMRI data of the ISO-group and RB-group were compared. For each individual image, the fixed effects analysis was performed based on the general linear model with a box-car response function as the reference waveform convolved with the canonical hemodynamic response function. Brain regions with significant BOLD changes were yielded based on a voxel-level height threshold of $P < 0.05$ (FWE corrected) and a cluster-extent threshold of five voxels.

Results

Physiological parameter recordings

In order to estimate the influence of RB and isoflurane, a bench study was conducted to monitor the physiological parameters of the subjects. The mean arterial blood pressure (MABP) and heart rate (HR) were recorded in the ISO+RB and RB states. The MABP and HR

Cerebral activities induced by rocuronium bromide

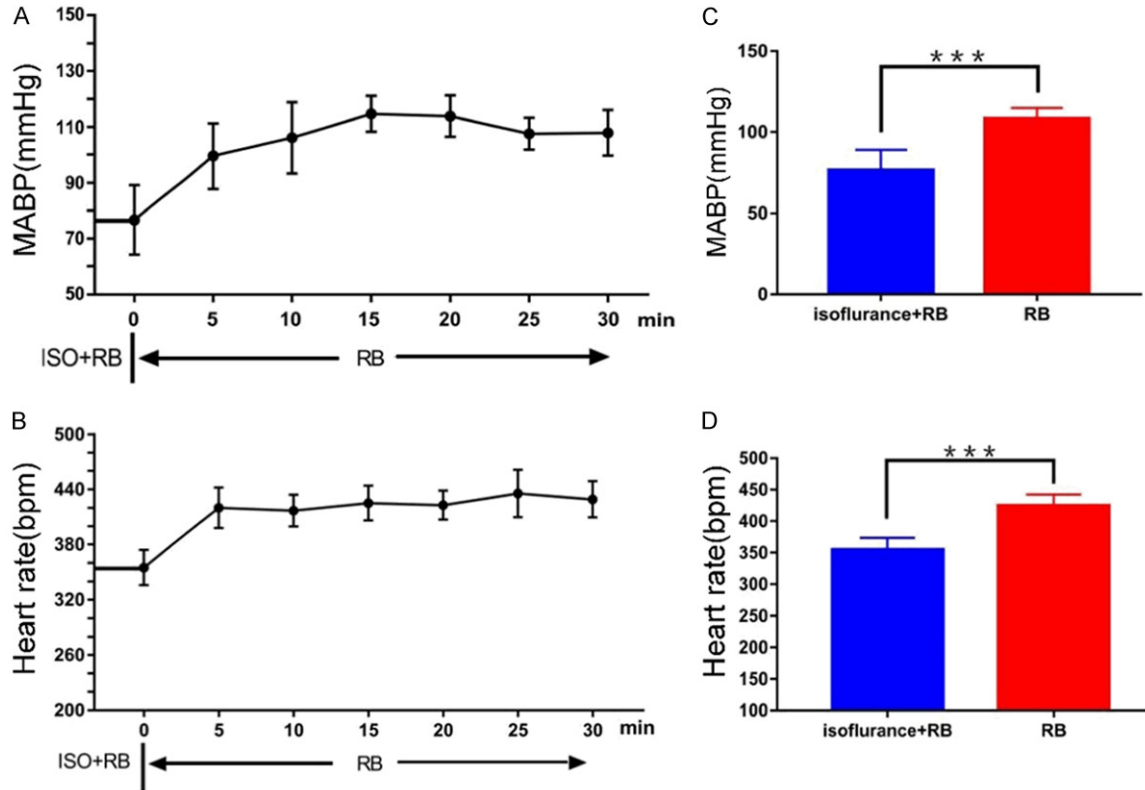


Figure 2. Comparisons of the physiological parameters of ISO+RB state and RB state. A and B. The MABP and HR quickly increased when isoflurane was removed. C and D. Significant differences were observed in MABP and HR when isoflurane was removed. Note: two-sample t-test, ‘***’ for $P < 0.001$; ISO: isoflurane; RB: Rocuronium bromide; MABP: Mean arterial blood pressure; HR: heart rate.

in the ISO+RB state were set at time-point 0 as shown on the graph (Figure 2A and 2B), and the x-axis represents the recovery period after isoflurane was turned off. The blood pressure rose rapidly when isoflurane was turned off, reaching the peak value after 15 min and remained stable during the following 30 min. The heart rate was also elevated and continuously increased, reaching the peak at 30 min. The time-point 0 and 30 were chosen to represent the ISO-group and the RB-group, the mean and variance of the MABP and the HR were calculated (Figure 2C and 2D). There were significant differences between the ISO-group (MABP: 76.7 ± 12.5 mmHg, HR: 355.1 ± 18.69 bpm, $n = 7$) and the RB-group (MABP: 108.3 ± 6.6 mmHg, HR: 425.0 ± 17.22 bpm, $n = 7$).

Oxygen saturation as the main factor involved in the maintenance of oxyhemoglobin formation also influenced the BOLD signal change. The oxygen saturation of each subject was

recorded during the induction of RB (Table S2).

The oxygen saturation of subjects was greater than 90%, which represented that enough oxygen was provided during the RB induced state.

Head motion estimation

The FD Jenkinson was used to estimate the movement of subjects during resting-state and task-state experiments [26]. An estimated value above 0.2 in the FD Jenkinson indicated that excessive head motion occurred during scanning. All three groups (ISO-group, RB-group, MED-group) underwent a stable state during the long scanning periods with the FD Jenkinson value of less than 0.2 (Figure 3, left upper). In particular, there was no abrupt change of the FD Jenkinson value when stimulation was given (Figure 3, 20-28 volume, marked by grey background), indicating that there was no obvious movement during the stimulation period. The mean FD

Cerebral activities induced by rocuronium bromide

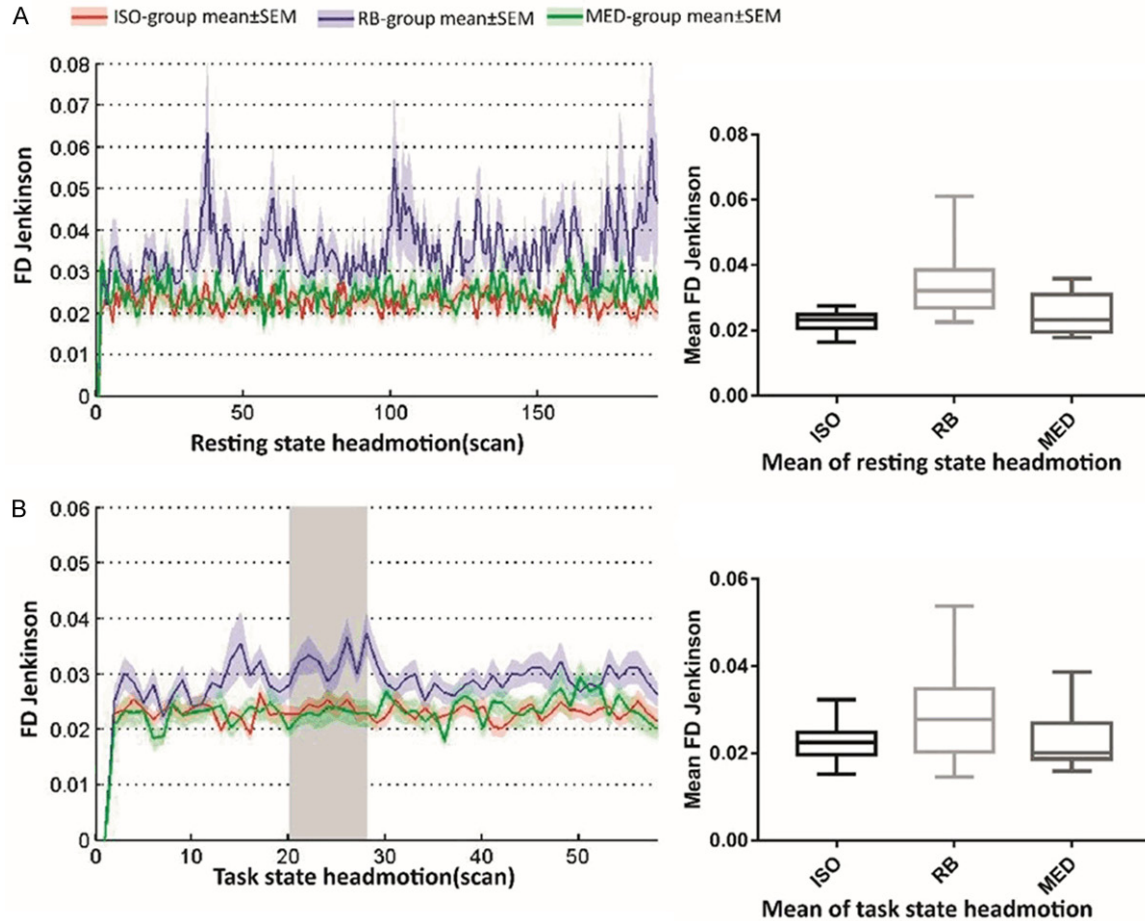


Figure 3. Comparisons of the head motion among three different groups (Red: ISO-group; Blue: RB-group; and Green: MED-group) during fMRI studies. Note: The FD Jenkinson values are illustrated in the whole scanning time with mean \pm SEM and the mean FD Jenkinson values for the different groups were calculated and shown in a box plot. A. Resting-state fMRI, the head motions were acceptable in all the groups (FD Jenkinson $<$ 0.2). B. Task-state fMRI, the head motion was also stable in both of the baseline and the stimulus given period (grey background); ISO: isoflurane; RB: Rocuronium bromide; Med: Dexmedetomidine.

Jenkinson values of the three groups are illustrated with a box figure (Figure 3, right side). Although greater head motion was found in the RB-group, it was acceptable when the maximum value was much lower than 0.2.

Task-state fMRI

As a well-studied pathway, the visual sensory pathway was used to measure the reaction of subjects when light stimulation was given [27, 28]. The *t*-stats of the student's test was used to represent the reaction strength of the three groups, and the significant (FDR $P < 0.05$) evoked regions were identified through group analysis. All groups showed significant activation of the left lateral geniculate body (DLG_L), which was the first station of visual signaling

transmission (Figure 4). The superior colliculus (SC) also responded in these three different groups, as it received direct projection from the optic nerve. However, there were more activated regions related with the visual system in the RB-group, such as the contralateral lateral geniculate body (DLG_R), spinothalamic (LDDM, VPL) and the visual cortex (V1, V2). In addition, responses to the DLG_L and the SC in the MED-group were stronger than in the other two groups (Figure 4), and responses in the RB-group were also stronger than in the ISO-group.

To investigate BOLD signal changes under light stimulation, the ROIs (region of interest) of the stimulated brain regions were extracted, including V2, V1, SC, DLG_L, DLG_R, MDI/Mhb,

Cerebral activities induced by rocuronium bromide

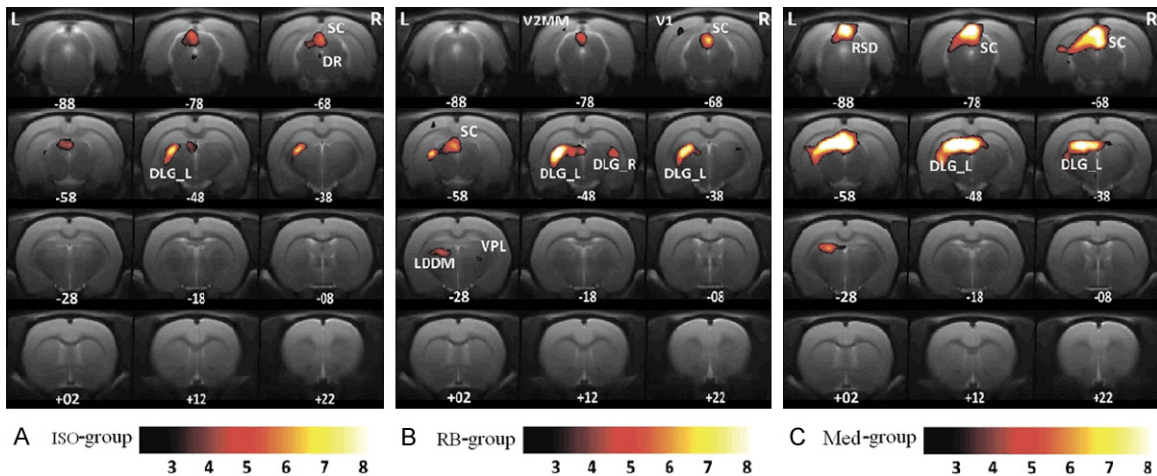


Figure 4. Cerebral activities during the task-state fMRI studies in the three different groups. Note: ISO: isoflurane; RB: Rocuronium bromide; Med: Dexmedetomidine; Group analysis of the significant evoked regions were shown by the permutation test, corrected by the TFCE $P < 0.05$. Only the DLG_L and SC were shown in the ISO-group (A) and MED-group (C), and the most widely evoked regions were found in the RB-group (B), such as DLG_R, V2, V1 and LDDM; DLG_L: the dorsal lateral geniculate nucleus (left); SC: superior colliculus; DLG_R: dorsal lateral geniculate nucleus (right); V2: secondary visual cortex; V1: primary visual cortex; and LDDM: the laterodorsal thalamic nucleus, the dorsomedial part.

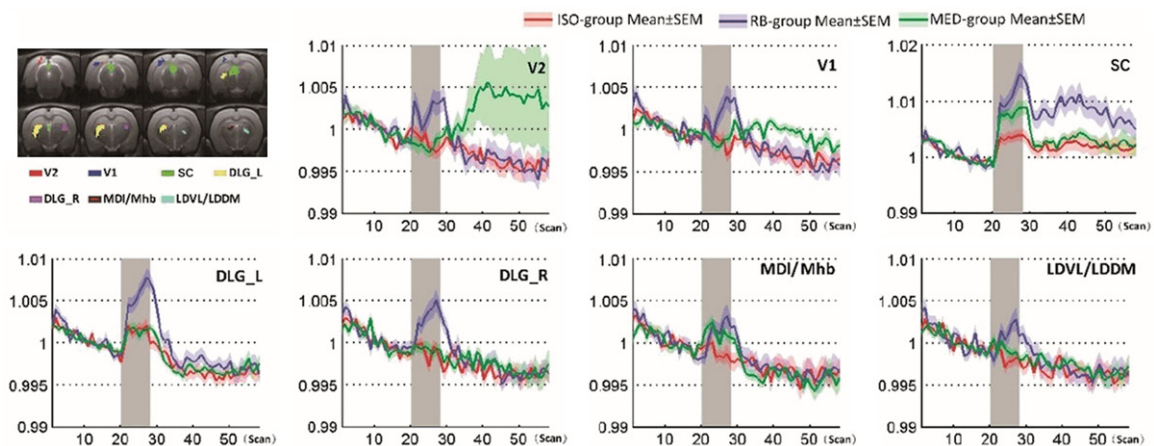


Figure 5. Time courses of the BOLD signals in the three different groups (ISO-group; red, RB-group; blue and MED-group; green) during the task-state fMRI study. Note: ISO: isoflurane; RB: Rocuronium bromide; Med: Dexmedetomidine; Left-top: Locations of the selected regions; V1: primary visual cortex; V2: secondary visual cortex; SC: superior colliculus; DLG_L: dorsal lateral geniculate nucleus (left); DLG_R: dorsal lateral geniculate nucleus (right); MDI/Mhb: mediodorsal thalamic nucleus, lateral part/medial habenular nucleus; LDVL/LDDM: laterodorsal thalamic nucleus, ventrolateral/dorsomedial part. There were obvious changes observed in the RB-group during the stimulus periods (grey background), and there were similar BOLD signal changes found in the regions of DLG_L and SC for ISO-group and MED-group.

LDVL/LDDM (Figure 5). As expected, signal changes of the regions DLG_L and SC could be found in all of the three groups. More regions were found in the MED-group, such as MDI/Mhb and LDVL/LDDM. However, the other visual-related regions such as V2, V1 and DLG_R could only be found in the RB-group. The signal

changed in the MDI/Mhb and LDVL/LDDM. On the other hand, the RB-group also showed stronger signal changes in those visual sensory related regions. It reached 2% signal changes in the region of SC in the RB-group, while the changes of the ISO-group and the MED-group were around 0.5%.

Cerebral activities induced by rocuronium bromide

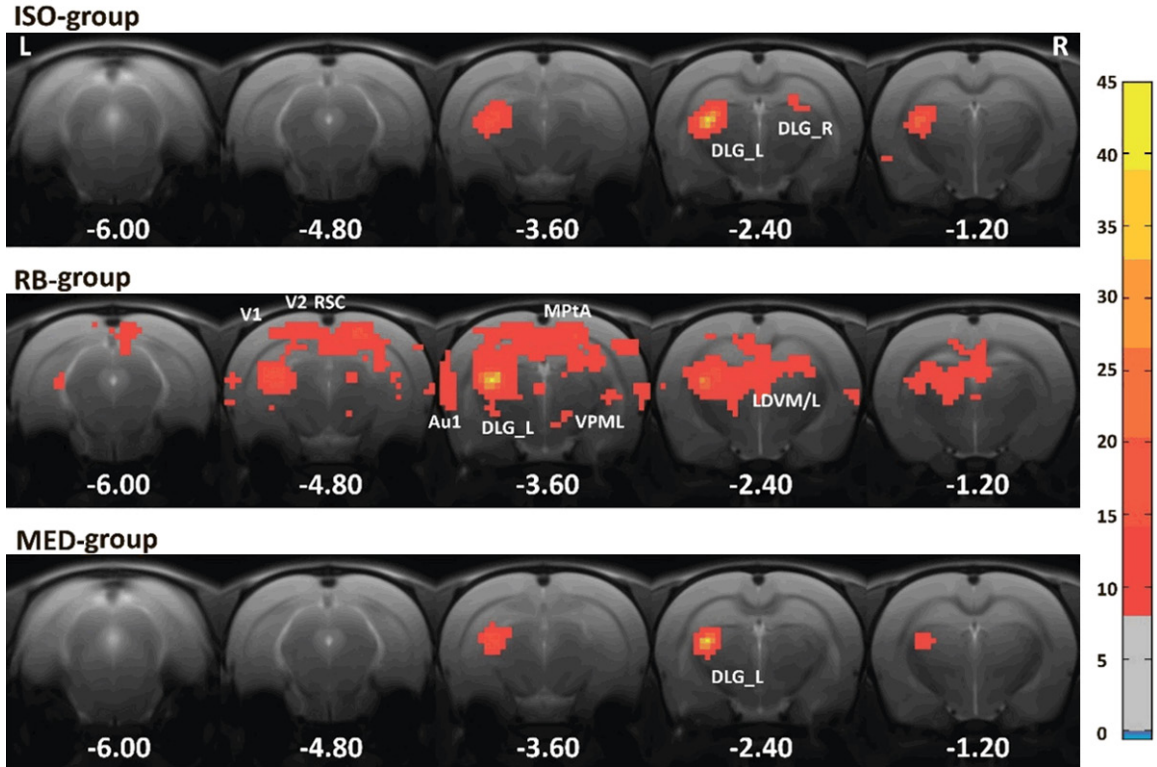


Figure 6. Functional connectivity for the specific ROI (DLG_L) in the three groups (ISO-group, RB-group and MED-group). Note: ISO: isoflurane; RB: Rocuronium bromide; Med: Dexmedetomidine; One-sample *t*-test (t -stats >8) was used to calculate the activated regions with DLG_L in each group. During the same threshold, the most widely connected regions could be found in the RB-group, and limited connected regions were illustrated for ISO-group and MED-group.

Voxel-wise resting-state fMRI

The functional connections of the brain in the resting-state fMRI were similar to those in the task-state fMRI. In order to explain the changes of the task state, the region of DLG_L was selected as the ROI, and the functional connections in the whole brain with DLG_L was calculated to estimate the spontaneous connections in these three groups. The statistic result was obtained using the one-sample *t*-test. In order to show the differences of the three groups, the regions were shown when the *t*-stats was greater than eight. There was a greater range of connections found in the RB-group (Figure 6). Most of them were related to the visual sensory pathway, such as DLG_R, LDVM/L, RSD/C and V2 while only weak connections were found in the ISO-group and MED-group, such as contralateral DLG (DLG_R).

ROI-wise resting-state fMRI

In order to investigate the differences of the whole brain activity in these three groups, 18

different brain regions were chosen as the regions of interest (ROIs, Table S1). All ROIs were carefully selected with an anatomical map of the rat brain [29]. The functional connectivity from ROI to ROI was calculated and the statistical results were obtained using multiple comparisons for one-way ANOVA, and the significant different connections were screened using the Dunnett-*t* test (hoc test) when $P < 0.05$. Each side of the voxel in the matrix represented one ROI (Figure 7). The color of each voxel represented the connection strength between two different ROIs, and the significant different regions compared to the RB-group was marked with a '*'. Many significant different regions could be found in the ISO-group and MED-group, such as the motor cortex (M12), parietal lobe (MPTA) and sensory cortex (S2). Significant change could also be found in the hippocampus of the MED-group. The top 9 significant different ROI pairs of the connectivity are shown (Figure 8), and the RB-group displayed the strongest functional connectivity among the 9 ROI pairs of the sensory network.

Cerebral activities induced by rocuronium bromide

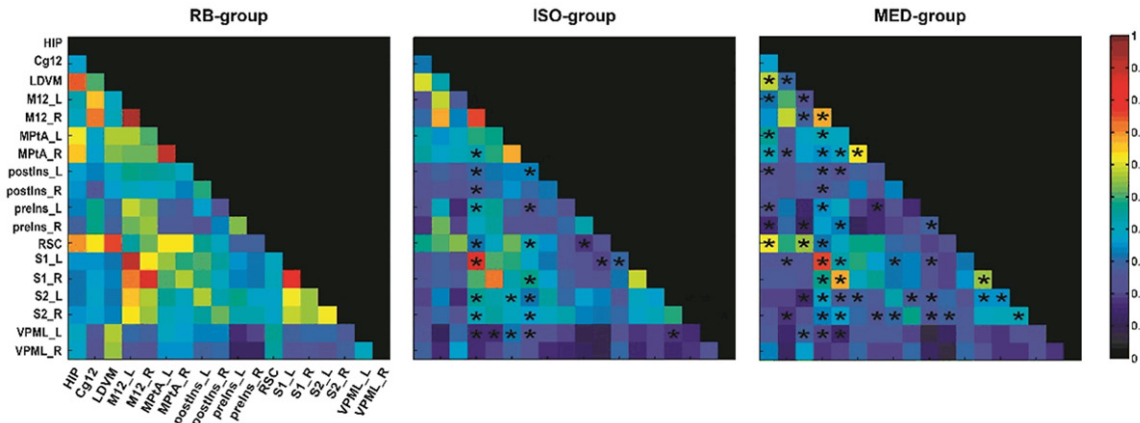


Figure 7. Comparison of the default network of ROI-wise resting-state fMRI in the three different groups (ISO-group, RB-group and MED-group). Note: Color of each block was represented with the mean functional connectivity strength of a pair of ROIs; *: The significant different pairs compared to the RB-group with one-way ANOVA and the post hoc test (Dunnnett-t test) comparison; Results showed that there were many pairs observed with significant differences in the groups of ISO and MED ($P < 0.05$, marked by '*'), and the mean values of functional connectivity for most of them were weaker than the RB-group.

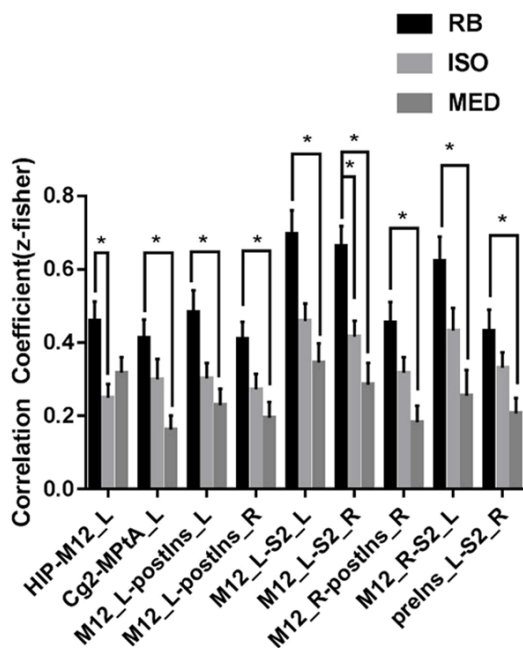


Figure 8. Functional connectivity of the top nine different pairs of ROI-wise resting-state fMRI analyzed in the three different groups. Note: Names of the abbreviations of brain regions were collected in [Table S1](#); *: $P < 0.05$ with One-way ANOVA and the post hoc test (Dunnnett-t test) between RB-group and the other two groups.

Fixed effects analysis of BOLD signal

In order to investigate the BOLD signal change between the isoflurane induced condition and

isoflurane free condition, fixed effects analysis was calculated in the whole brain range using resting state data in the ISO-group and RB-group (**Figure 9**). When animals revived from isoflurane anesthesia, increased bold signals were found in the cortical regions, such as the motor cortex, somatosensory cortex, visual cortex and the auditory cortex. At the same time, decreased signals could be found in the thalamus and periaqueductal gray in the midbrain. Furthermore, the signal changes (both that increased and decreased) in the brain wide maps were almost symmetrical, which improved the reliability of the results.

Discussion

A robust fMRI reaction induced by RB was proposed in the current study. The whole-brain resting connectivity and visual stimulation of three different anesthesia protocols were investigated, including RB induced, RB and isoflurane mixing induced, and dexmedetomidine induced. Results showed that the RB induced group had the highest brain network connectivity compared with the other two groups, and the BOLD signal changed when the animal was revived from isoflurane.

Physiological parameters

The physiological parameters were used to investigate the recovery time of the animal

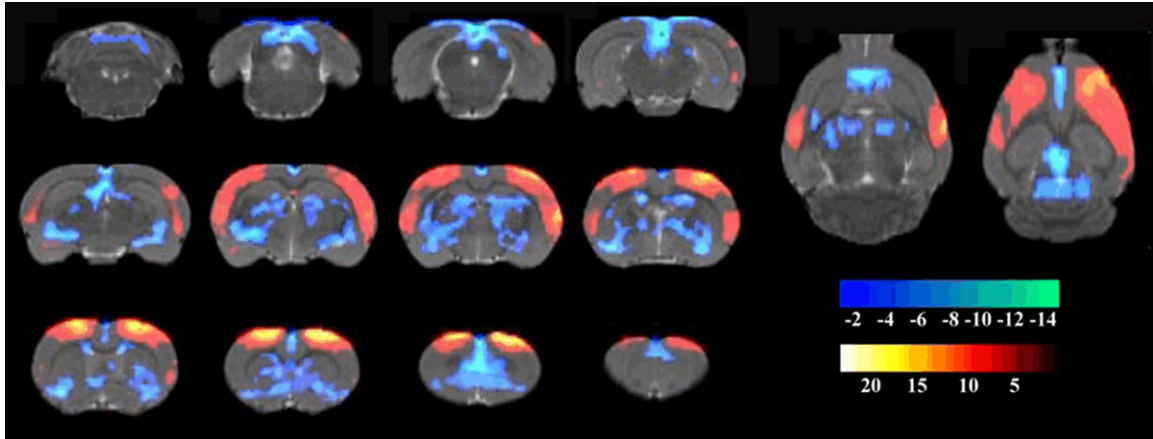


Figure 9. Changes of the BOLD signal when subjects were revived from isoflurane. Note: Higher BOLD signal was observed in the cortex region when isoflurane was removed (ISO-group < RB-group), and lower BOLD signals were found in most of the thalamus region and the periaqueductal gray in the midbrain (ISO-group > RB-group).

from the isoflurane induced condition and the isoflurane free condition. The blood pressure and heart rate were taken into consideration at the same time to estimate a suitable waiting time in the MRI scanner. When isoflurane was turned off, the heart rate of the animal recovered quickly and become stable within 5 min while the blood pressure kept rising in 5-15 min. Therefore, we finally chose 30 min as the waiting time in the MRI scanner because the data was stable within 25-30 min. Besides, the measured values were similar to those of a previous study which reported normal blood pressure to be around 130 mmHg and the heart rate around 440 bpm [30].

Application of anesthetics

As one kind of a neuromuscular blocking agent or muscle relaxant, RB is commonly used in modern anesthesia to facilitate rapid tracheal intubation or rapid sequence induction by providing skeletal muscle relaxation [21, 22]. Currently, RB was used as a muscle relaxant to keep the immovable state of the animal during fMRI scanning. The dosage of RB was tested in a bench study assessing when an animal cannot respond to toes pinching. The isoflurane was given using a minimal dose to maintain anesthesia. The dexmedetomidine was given using a dosage which was reported to have a robust reaction in an fMRI study [31] while lidocaine was administered during oral tracheal intubation to minimize stimulation to the throat.

Visual response in the fMRI study

In all of the three groups (ISO-group, RB-group and MED-group), visually evoked BOLD signal changes were investigated after direct laser stimulation of the right eye. As expected, the DLG (left) and SC were activated in all of the three group (**Figure 3**), which were involve in the visual sensory [28, 32]. Retinal ganglion cells (RGCs), which receive treated visual information from the eyes as the primary visual neurons, are connect to lateral geniculate nucleuses (DLG) and superior colliculus (SC) through retinal recipient neurons. In addition, the RB-group showed more regional responses in the DLG_R, V1, V2, LDDM and VPL. Among those regions, the activation of DLG_R may come from the ipsilateral projection or bilateral communication from DLG_L. The V1 and V2 were the higher sensory region that received the message from DLG, and the thalamus region (LDDM, VPL) was involved in sensation [33]. The time course of the BOLD signal in the task-state fMRI also supports the results because the ISO-group only showed significant changes in the DLG_L and SC region whereas, the RB-group showed significant changes in all selected regions. Moreover, the robust spontaneous connections between advanced visual sensory regions (V1, V2) and DLG_L were only found in the RB-group (**Figure 5**). The strength of the higher spontaneous connections of those regions may have led to the activation of V1 and V2 task-state fMRI in the RB-group.

Default mode network under anesthesia

Resting state fMRI studies have illustrated that the default mode network of the brain is varied in different states, such as awake, anesthesia and sleep [34]. Here the default mode network involved in the somatosensory was investigated. The results showed that stronger functional connections in the whole brain could be obtained in the RB-group. All the functional connectivity strength in the ISO-group and MED-group were restricted because isoflurane and dexmedetomidine were able to influence brain activity [35, 36]. As shown in **Figure 6**, the top 3 affected regions between the RB-group and ISO-group were the motor cortex, parietal cortex and lateral spinothalamic. Those regions were respectively responsible for movement [37], procession of visual information [38] and input of sensory information [39]. The top 3 affected regions between the RB-group and MED-group were the motor cortex, secondary sensory cortex and lateral spinothalamic. Those regions were responsible for movement, high-class procession of sensory information [39] and input of sensory information.

The BOLD signal change occurred in the ISO-group and RB-group, and the increased BOLD signal was found in the cortex area, but was decreased in thalamus regions. The result is similar to previous findings which reported that the function of the cortex can be inhibited in the anesthesia state [34] and the thalamus activated in the rapid eye movement state [40].

Conclusion

The fMRI study investigated the simple use of RB (RB-group) in the current study. When comparing two commonly used anesthesia protocols (ISO-group and MED-group), the RB-group showed stronger and more expected results than the other two groups. While the simple use of RB in an fMRI study was not advised, the stress levels of animals was still a problem due to the noisy environment from mechanical ventilation. A low dosage of anesthesia mixed with RB maybe a better option in order to obtain robust fMRI data and at the same time minimize animal stress.

Acknowledgements

This work was supported by the National Natural Science Foundation of China (317-

71193, 81974170, 81671770) and the Youth Innovation Promotion Association of Chinese Academy of Sciences (Y6Y0021004).

Disclosure of conflict of interest

None.

Address correspondence to: Xuebi Tian, Department of Anesthesiology, Tongji Hospital, Tongji Medical College, Huazhong University of Science and Technology, Jiefang Avenue 1095#, Wuhan 430070, Hubei, P. R. China. Tel: +86-27-83663282; Fax: +86-27-83663173; E-mail: tianxb@hust.edu.cn; Jie Wang, Hebei Provincial Key Laboratory of Basic Medicine for Diabetes, 2nd Hospital of Shijiazhuang, 30 West of Xiao Hong Shan Street, Shijiazhuang 050051, Hebei, P. R. China. Tel: +86-27-87197653; Fax: +86-27-87199543; E-mail: jie.wang@wipm.ac.cn

References

- [1] Barttfeld P, Uhrig L, Sitt JD, Sigman M, Jarraya B and Dehaene S. Signature of consciousness in the dynamics of resting-state brain activity. *Proc Natl Acad Sci U S A* 2015; **112**: 887-892.
- [2] Wager TD, Rilling JK, Smith EE, Sokolik A, Casey KL, Davidson RJ, Kosslyn SM, Rose RM and Cohen JD. Placebo-induced changes in fMRI in the anticipation and experience of pain. *Science* 2004; **303**: 1162-1167.
- [3] Baliki MN, Geha PY and Apkarian AV. Parsing pain perception between nociceptive representation and magnitude estimation. *J Neurophysiol* 2009; **101**: 875-887.
- [4] Lukasik VM and Gillies RJ. Animal anaesthesia for in vivo magnetic resonance. *NMR Biomed* 2003; **16**: 459-467.
- [5] Maggi CA and Meli A. Suitability of urethane anesthesia for physiopharmacological investigations in various systems. Part 1: General considerations. *Experientia* 1986; **42**: 109-114.
- [6] Boveroux P, Vanhaudenhuyse A, Bruno MA, Noirhomme Q, Lauwick S, Luxen A, Degueldre C, Plenevaux A, Schnakers C, Phillips C, Brichant JF, Bonhomme V, Maquet P, Greicius MD, Leureys S and Boly M. Breakdown of within- and between-network resting state functional magnetic resonance imaging connectivity during propofol-induced loss of consciousness. *Anesthesiology* 2010; **113**: 1038-1053.
- [7] Schlegel F, Schroeter A and Rudin M. The hemodynamic response to somatosensory stimulation in mice depends on the anesthetic used: Implications on analysis of mouse fMRI data. *NeuroImage* 2015; **116**: 40-49.
- [8] Masamoto K, Fukuda M, Vazquez A and Kim SG. Dose-dependent effect of isoflurane on

Cerebral activities induced by rocuronium bromide

- neurovascular coupling in rat cerebral cortex. *Eur J Neurosci* 2009; 30: 242-250.
- [9] Gao YR, Ma Y, Zhang Q, Winder AT, Liang Z, Antinori L, Drew PJ and Zhang N. Time to wake up: studying neurovascular coupling and brain-wide circuit function in the un-anesthetized animal. *NeuroImage* 2017; 153: 382-398.
- [10] Madularu D, Mathieu AP, Kumaragamage C, Reynolds LM, Near J, Flores C and Rajah MN. A non-invasive restraining system for awake mouse imaging. *J Neurosci Methods* 2017; 287: 53-57.
- [11] Mansour A, Baria AT, Tetreault P, Vachon-Présseau E, Chang PC, Huang L, Apkarian AV and Baijki MN. Global disruption of degree rank order: a hallmark of chronic pain. *Sci Rep* 2016; 6: 34853.
- [12] Ferris CF, Febo M, Luo F, Schmidt K, Brevard M, Harder JA, Kulkarni P, Messenger T and King JA. Functional magnetic resonance imaging in conscious animals: a new tool in behavioural neuroscience research. *J Neuroendocrinol* 2006; 18: 307-318.
- [13] Ferenczi EA, Zalocusky KA, Liston C, Grosenick L, Warden MR, Amatya D, Katovich K, Mehta H, Patenaude B, Ramakrishnan C, Kalanithi P, Etkin A, Knutson B, Glover GH and Deisseroth K. Prefrontal cortical regulation of brainwide circuit dynamics and reward-related behavior. *Science* 2016; 351: aac9698.
- [14] Sumiyoshi A, Keeley RJ and Lu H. Physiological considerations of functional magnetic resonance imaging in animal models. *Biol Psychiatry Cogn Neurosci Neuroimaging* 2018; 4: 522-532.
- [15] Brown EN, Purdon PL and Van Dort CJ. General anesthesia and altered states of arousal: a systems neuroscience analysis. *Annu Rev Neurosci* 2011; 34: 601-628.
- [16] Ching S and Brown EN. Modeling the dynamical effects of anesthesia on brain circuits. *Curr Opin Neurobiol* 2014; 25: 116-122.
- [17] Brown EN, Lydic R and Schiff ND. General anesthesia, sleep, and coma. *N Engl J Med* 2010; 363: 2638-2650.
- [18] Liang Z, Watson GD, Alloway KD, Lee G, Neuberger T and Zhang N. Mapping the functional network of medial prefrontal cortex by combining optogenetics and fMRI in awake rats. *NeuroImage* 2015; 117: 114-123.
- [19] Becerra L, Chang PC, Bishop J and Borsook D. CNS activation maps in awake rats exposed to thermal stimuli to the dorsum of the hindpaw. *NeuroImage* 2011; 54: 1355-1366.
- [20] Low LA, Bauer LC, Pitcher MH and Bushnell MC. Restraint training for awake functional brain scanning of rodents can cause long-lasting changes in pain and stress responses. *Pain* 2016; 157: 1761-1772.
- [21] Johnson EG, Meier A, Shirakbari A, Weant K and Justice SB. Impact of rocuronium and succinylcholine on sedation initiation after rapid sequence intubation. *J Emerg Med* 2015; 49: 43-49.
- [22] Tran DTT, Newton EK, Mount VAH, Lee JS, Mansour C, Wells GA and Perry JJ. Rocuronium vs. succinylcholine for rapid sequence intubation: a cochrane systematic review. *Anaesthesia* 2017; 72: 765-777.
- [23] Ferrari L, Turrini G, Crestan V, Bertani S, Cristofori P, Bifone A and Gozzi A. A robust experimental protocol for pharmacological fMRI in rats and mice. *J Neurosci Methods* 2012; 204: 9-18.
- [24] Nie B, Liu H, Chen K, Jiang X and Shan B. A statistical parametric mapping toolbox used for voxel-wise analysis of FDG-PET images of rat brain. *PLoS One* 2014; 9: e108295.
- [25] Nie B, Chen K, Zhao S, Liu J, Gu X, Yao Q, Hui J, Zhang Z, Teng G, Zhao C and Shan B. A rat brain MRI template with digital stereotaxic atlas of fine anatomical delineations in paxinos space and its automated application in voxel-wise analysis. *Hum Brain Mapp* 2013; 34: 1306-1318.
- [26] Jenkinson M, Bannister P, Brady M and Smith S. Improved optimization for the robust and accurate linear registration and motion correction of brain images. *NeuroImage* 2002; 17: 825-841.
- [27] Jorge J, Figueiredo P, Gruetter R and van der Zwaag W. Mapping and characterization of positive and negative BOLD responses to visual stimulation in multiple brain regions at 7T. *Hum Brain Mapp* 2018; 39: 2426-2441.
- [28] Niranjana A, Christie IN, Solomon SG, Wells JA and Lythgoe MF. fMRI mapping of the visual system in the mouse brain with interleaved snapshot GE-EPI. *NeuroImage* 2016; 139: 337-345.
- [29] Papp EA, Leergaard TB, Calabrese E, Johnson GA and Bjaalie JG. Waxholm space atlas of the sprague dawley rat brain. *NeuroImage* 2015; 97: 374-386.
- [30] Duong TQ. Cerebral blood flow and BOLD fMRI responses to hypoxia in awake and anesthetized rats. *Brain Res* 2007; 1135: 186-194.
- [31] Weber R, Ramos-Cabrera P, Wiedermann D, van Camp N and Hoehn M. A fully noninvasive and robust experimental protocol for longitudinal fMRI studies in the rat. *NeuroImage* 2006; 29: 1303-1310.
- [32] Lindsey JD, Scadeng M, Dubowitz DJ, Crowston JG and Weinreb RN. Magnetic resonance imaging of the visual system in vivo: transsynaptic illumination of V1 and V2 visual cortex. *NeuroImage* 2007; 34: 1619-1626.

Cerebral activities induced by rocuronium bromide

- [33] Rosa MG and Krubitzer LA. The evolution of visual cortex: where is V2? *Trends Neurosci* 1999; 22: 242-248.
- [34] Nallasamy N and Tsao DY. Functional connectivity in the brain: effects of anesthesia. *Neuroscientist* 2011; 17: 94-106.
- [35] Liang ZF, King J and Zhang NY. Intrinsic organization of the anesthetized brain. *J Neurosci* 2012; 32: 10183-10191.
- [36] Liu XA, Zhu XH, Zhang Y and Chen W. Neural origin of spontaneous hemodynamic fluctuations in rats under burst-suppression anesthesia condition. *Cereb Cortex* 2011; 21: 374-384.
- [37] Li N, Chen TW, Guo ZV, Gerfen CR and Svoboda K. A motor cortex circuit for motor planning and movement. *Nature* 2015; 519: 51-56.
- [38] Wilber AA, Clark BJ, Demecha AJ, Mesina L, Vos JM and McNaughton BL. Cortical connectivity maps reveal anatomically distinct areas in the parietal cortex of the rat. *Front Neural Circuits* 2015; 8: 146.
- [39] Garcia-Larrea L and Peyron R. Pain matrices and neuropathic pain matrices: a review. *Pain* 2013; 154: S29-S43.
- [40] Zhurakovskaya E, Paasonen J, Shatillo A, Lipponen A, Salo R, Aliev R, Tanila H and Grohn O. Global functional connectivity differences between sleep-like states in urethane anesthetized rats measured by fMRI. *PLoS One* 2016; 11: e0155343.

Cerebral activities induced by rocuronium bromide

Table S1. List of 28 selected regions of interested (ROIs) in the whole brain for resting state analysis

Number	Abbreviation	Full Name
1	HIP	hippocampus
2	Cg12	cingulate cortex, area 1; cingulate cortex, area 2
3	LDVM/L	laterodorsal thalamic nucleus, dorsomedial part; laterodorsal thalamic nucleus, ventrolateral part
4	M12_L	primary motor cortex (left); secondary motor cortex (left)
5	M12_R	primary motor cortex (right); secondary motor cortex (right)
6	MPtA_L	medial parietal association cortex (left)
7	MPtA_R	medial parietal association cortex (right)
8	postIns_L	insular cortex (left, bregma 0 mm to -2.92 mm)
9	postIns_R	insular cortex (right, bregma 0 mm to -2.92 mm)
10	preIns_L	insular cortex (left, bregma 4.20 mm to 0 mm)
11	preIns_R	insular cortex (right, bregma 4.20 mm to 0 mm)
12	RSC	retrosplenial granular cortex
13	S1HL_L	primary somatosensory cortex, hindlimb region (left)
14	S1HL_R	primary somatosensory cortex, hindlimb region (right)
15	S2_L	secondary somatosensory cortex (left)
16	S2_R	secondary somatosensory cortex (right)
17	VPML_L	ventral posteromedial thalamic nucleus (left); ventral posterolateral thalamic nucleus (left)
18	VPML_R	ventral posteromedial thalamic nucleus (right); ventral posterolateral thalamic nucleus (right)

Table S2. Oxygen saturation of each subject of arterial blood in the induction of rocuronium bromide

Subject Number	Oxygen saturation (%)
1	95.8
2	96.1
3	97.1
4	95.5
5	97.6
6	96.8
7	97.3